

Case Report

Giant Pulmonary Hernia Repair With Mesh And Latissimus Flap

*Sala Hernández A¹, Estors Guerrero M^{2,4}, Martínez Hernandez NJ², Bistoni G³, Galbis JM^{2,4}

¹Cirugía General y del Aparato Digestivo del Hospital Universitario y Politécnico la Fe, Valencia.

²Servicio de Cirugía Torácica². Hospital Universitario La Ribera. Crta Corbera km1. 46600 Alcira, Valencia

³Servicio de Cirugía Plástica³. Hospital Universitario La Ribera. Crta Corbera km1. 46600 Alcira, Valencia

⁴Medicina y Cirugía Aparato Respiratorio. Grado de Medicina Grado UCV

Received May 28, 2017; Accepted November 21, 2017; Published November 23, 2017

Copyright: © 2017 Sala Hernández, et al.

Abstract

Pulmonary hernia is a rare entity caused in most cases by a thoracic traumatism. Clinical diagnosis is critical, which together with a precedent traumatism should raise suspicions on it. Confirmation is done by imaging, where CT is particularly relevant in defining its relationship with neighboring structures. In this manuscript we present a patient with rib fracture due to a traffic accident that derived into pulmonary hernia. Due to hernia recurrence, the patient underwent three surgical procedures. In the last intervention, a double repair was performed using prosthetic material plus dorsal reinforcement flap.

Key Words: Traumatic pulmonary hernia; latissimus flap

Case Report

A 56-year-old male was diagnosed with left chronic pulmonary hernia after a motorbike traffic accident. Among others, in his medical history stand diabetes, obesity and dilated myocardiopathy.

Pulmonary hernia was diagnosed after a traffic accident that caused fractures in the lateral portion of the 7th and 8th ribs and in the back of the 9th, 10th and 11th ribs of the left hemi-thorax. Two months later, after a catarrhal episode, he consulted due to pain and left thoracic lump that grew when Valsalva maneuvers were applied. In light of the symptoms and the traumatic history, pulmonary hernia was considered, which was confirmed after radiological examinations.

CT-scan revealed rib fractures and left posterior pulmonary hernia between the 8th and 9th costal angles with diameters 43x55x26 mm. (Figure 1 and 2)

Hernia repair took place when the patient's cardiac comorbidity allowed a safe surgical procedure.

At first, the surgical reparation consisted of cerclage with

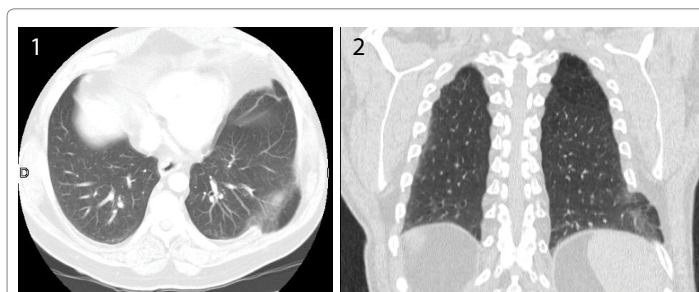

Figure 1, 2:- CT: pulmonary hernia.

independent stitches made with absorbable suture anchored to the ribs. During the follow-up, relapse was detected 10 months after surgery. The patient underwent another surgical intervention, which consisted of metallic cerclage and the placement of a goretex mesh anchored to muscular planes. One year later a second symptomatic relapse was diagnosed, thus, indicating new surgical repair.

Intraoperative findings included a very weakened thoraco-abdominal wall, with no previous mesh integration and an important defect between the 8th and 9th ribs. Therefore, the mesh was removed and the hernia was repaired with a polypropylene double mesh added to a latissimus dorsi flap. (Figure 3 and 4) No postoperative complications occurred and the patient was discharged after the 4th postoperative day.

***Corresponding Author:** Sala Hernández A, Cirugía General y del Aparato Digestivo del Hospital Universitario y Politécnico la Fe, Valencia, Tel:- + 620120835, Fax: 246240 Hospital Universitario y Politécnico la Fe (Valencia), E-mail: asalahdez@gmail.com

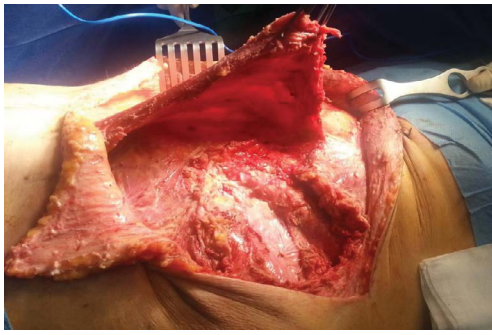


Figure 3:- Arrow: latissimus dorsi flap. Asterisk: Defect muscle wall.

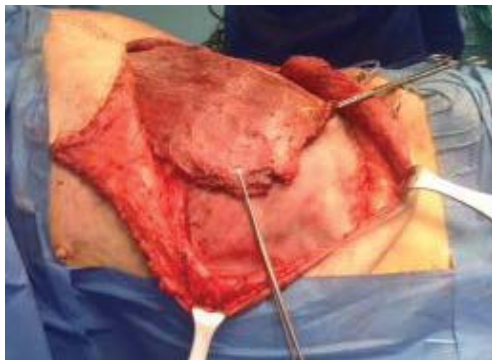

Figure 4:- Latissimus dorsi flap. Asterisk: mesh.

After 18 months of follow-up no hernia recurrence has been detected.

Discussion

Pulmonary hernias are uncommon findings in the medical literature, defined as a protrusion of pulmonary tissue through a defect in the thoracic wall.

Pulmonary hernias were classified according to their anatomic localization and etiology by Morel-Lavalle in 1845 [1]. Cervical hernias are usually congenital and they need no active treatment. Thoracic hernias are resolved spontaneously where there is only one layer of intercostal muscle [2]. An increase in the frequency of intercostal hernia has been described after mini-invasive surgical procedures such as thoracoscopy [3].

Risk factors for developing spontaneous hernia are the sudden increase of intrathoracic pressure, which happens after cough episodes or after playing wind instruments, on a weakened thoracic cage because of a rib fracture or a cartilage fracture [4].

According to the previous classification our case corresponds to an acquired pulmonary hernia due to the combination of an increase in the thoracic pressure (probably after a coughing episode) and the traumatism previously mentioned.

Pain is the most common symptom, which in addition to the

appearance of a flossy lump that increases its size during coughing episodes or Valsalva maneuvers makes pulmonary hernia a possible diagnosis. Within differential diagnosis, other conditions must be considered, such as subcutaneous emphysema, abscess and lipoma of the thoracic wall and cutaneous metastasis.

No consensus has been reached according to the treatment of this disease. Some authors favor surgical treatment as the best technique in order to prevent complications [5], while others consider that its management depends on the symptoms, the localization and the size of the hernia.

CT scan determines the amplitude of the herniated tissue, its topography and possible complications, important aspects that help define the surgical approach.

Although some conservative treatments, such as fixation with bandage, have also been reported, their success remains controversial. Immobilizing binding has been described as the first treatment in cases of pulmonary hernia, since it could achieve the spontaneous closure of the wall defect [6]. When conservative treatment fails, in larger defects, or in case of complications such as incarceration, surgical reparation is preferred. Our patient presented a large sized thoracic wall defect, so a surgical intervention was needed [7].

Several procedures have been described for surgical reparation for pulmonary hernia, although there is no consensus as to the most appropriate procedure. Surgical repair including primary closure with non-absorbable suture or hernioplasty employing a prosthetic mesh [8].

Prosthetic mesh and muscular flaps must be considered for repairing large or recurrent defects [8, 9]. Also, surgical repair employing video-assisted surgery has been described occasionally in selected cases. [10, 11]

Since our patient presented recurrence after employing a previous mesh reparation technique and a very weakened muscular wall, a double reparation was selected, using prosthetic mesh and reinforcement with latissimus dorsi flap. No references that approve or disprove this procedure have been found in the literature.

References

1. D. Tack A, Wattiez JC, Schtickzelle C, Delcour (2000) Spontaneous lung herniation after a single cough. *Eur. Radiol.* 10: 500-502.
2. Lang-Lazdunski L, Bonnet PM, Pons F, Brinquin L, Jancovici R (2002) Traumatic extrathoracic lung herniation. *Ann Thorac Surg*, 74: 927-929.
3. Athanassiadi K, Bagaev E, Simon A, Haverich A (2008) Lung herniation: a rare complication in minimally invasive cardiothoracic surgery. *Eur J Cardiothorac Surg*, 33: 774-6
4. Sonett JR, O'Shea MA, Caushaj PF, Kulkarni MG, Sandstrom SH (1994) Hernia of the lung: case report and literature review. *Ir J Med Sci*, 163: 410-412.

5. Szentkereszty Z, Boros M, Sápy P, Kiss SS (2002) Surgical treatment of intercostal hernia with implantation of polypropylene mesh, 10: 354-356.
6. Motta Ramírez G, Gaytán Ortiz A (2014) Hernia pulmonar intercostal. *Acta Médica Grupo Ángeles*. 12: 2-6.
7. Martínez Serna I, Mariscal de Alba MA, Hermoso Alarza F, Ávila Martínez RJ, Marrón Fernández MC, et al., (2012) Hernia pulmonar intercostal espontánea secundaria a cuadro de tos. *Rev Patol Resp*, 15: 89-91
8. Szentkereszty Z, Boros M, Sápy P, Kiss SS (2006) Surgical treatment of intercostal hernia with implantation of polypropylene mesh. *Hernia*, 10: 354-356.
9. Steven T Lanier, Meredith Wetterau, Eduardo Smith-Singares, Thomas Bilfinger, James Vosswinkel, Marc J Shapiro, Alexander B Dagum (2011) Management of pulmonary hernia through a flail segment in closed thoracic trauma using open reduction, internal fixation and pectoralis major flap reconstruction: A case report. *Can J Plast Surg*, 19: 145-149
10. Hebra A, Cina R, Streck C (2011) Video-assisted thoracoscopic repair of a lung hernia in a child. *J Laparoendosc Adv Surg Tech A*, 21:763-765.
11. Reardon MJ, Fabré J, Reardon PR, Baldwin JC (1998) Video-assisted repair of a traumatic intercostal pulmonary hernia. *Ann Thorac Surg*. 65: 1155-1157.